

LETTER TO THE EDITOR

Open Access



What did Sun Yat-sen really die of? A re-assessment of his illness and the cause of his death

Rolf F. Barth^{1*} and Jie Chen²

Abstract

This year is the 150th anniversary of the birth of Sun Yat-sen (November 12, 1866) and the 91st year following his death (March 12, 1925). It generally has been believed that the cause of his death was “liver cancer.” However, as indicated in the official autopsy report, dated March 13, 1925, of the Peking Union Medical College Hospital (PUMCH) in Beijing, the cause of his death in reality was an adenocarcinoma of the gallbladder with direct extension to the liver and diaphragm as well as widespread metastases to the peritoneal cavity. This important piece of information seems to have never been reported in the English language literature, and it was only in 2013 that the true cause of his death was stated in a one-line sentence in a non-medical Chinese online source. It had been mistakenly believed that the cause of Dr. Sun’s death was liver cancer, based on the observations made following an exploratory laparotomy, which had been performed at PUMCH on January 26, 1925. The purpose of this short report is to provide more details relating to his terminal illness and to correct the historical record for a medical audience as to the cause of the death of Sun Yat-sen, a very important figure in the history of 20th century China.

Keywords: Sun Yat-sen, Terminal illness, Autopsy, Cause of death, Adenocarcinoma of the gallbladder

Background

One of us (RFB) visited the Sun Yat-sen Memorial Hall in Guangzhou, China in early May 2016. Among the many items in the exhibition hall display cases relating to the life and accomplishments of Dr. Sun was a barely legible, one-page document that was of special interest to us as pathologists. It was a poor-quality, carbon copy of the autopsy report on Sun Yat-sen (Fig. 1), dated March 13, 1925, who had died at 9:00–9:30 a.m. on March 12, 1925 in Beijing. A limited autopsy was performed at the PUMCH by James R. Cash, MD, an associate professor in the Department of Pathology. This report, written in English (Fig. 2), indicated that the anatomic diagnoses were as follows:

“adenocarcinoma of the gallbladder with obstruction of the cystic duct; direct extension to liver and diaphragm; widespread metastasis to lungs, peri-

toneum, wall of ileum and colon; multiple constrictions of colon by carcinoma; healed cholecystitis; cholelithiasis; moderate generalized arteriosclerosis; slight diffuse scarring of the kidneys; cyst of left kidney; healed calcified tuberculosis of lungs; slight atrophy of heart; emphysema of lungs; ascites; pulmonary oedema; ascariasis [sic ascariasis].”

The diagnosis of adenocarcinoma of the gallbladder was completely unexpected by us, since it had been widely reported in obituaries such as those in *The New York Times* dated March 12, 1925 (Fig. 3) [1], *TIME* magazine dated March 23, 1925 [2], and the Chinese newspaper *Qun Qiang Bao* dated March 15, 1925 [3], that “Dr. Sun had for some time been suffering from cancer of the liver.” It was further stated in *The New York Times* article [1] that surgeons operated on Dr. Sun at the “Rockefeller Hospital,” or as it also was known, PUMCH, on January 26, 1925, and it was declared that his case was hopeless and he only had 10 days to live. However, he was still alive after 10 days, although weaker.

*Correspondence: rolf.barth@osumc.edu

¹ Department of Pathology, The Ohio State University, Columbus, OH 43210, USA

Full list of author information is available at the end of the article

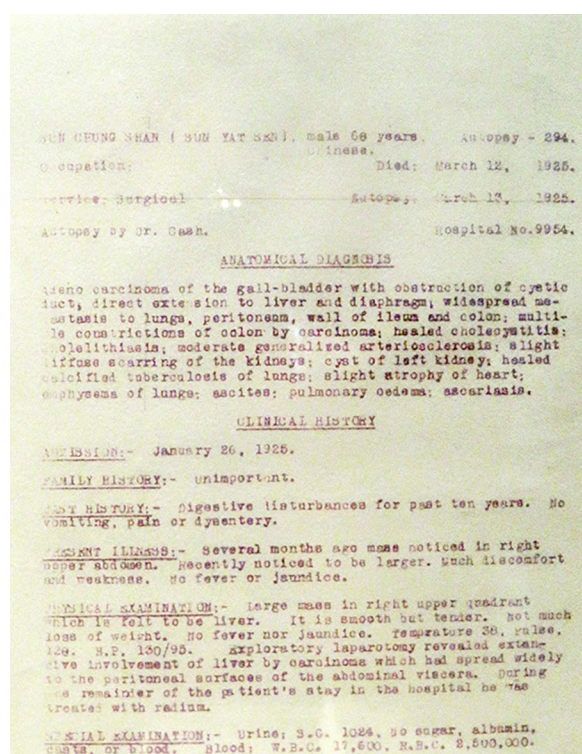


Fig. 1 A barely legible copy of the autopsy report on Sun Yat-sen that is on display in the Sun Yat-sen Memorial Hall

Clinical history

Assuming that they still exist, the original Autopsy Report and medical records relating to Dr. Sun's illness could not be located at the time of the writing of this report. On the other hand, the Seventeenth Annual Report for the year of 1925 of PUMCH has survived [4], but it sheds no light on the clinical history and autopsy of Dr. Sun. In the brief clinical history of Dr. Sun's illness drafted by Dr. Cash (Figs. 1 and 2), it was stated "that several months earlier a mass had been noted in the right upper abdomen, and that shortly before he was operated on it was noted to be larger and causing him much discomfort and weakness. Physical examination prior to his surgery revealed a large mass in the right upper quadrant of his abdomen and this was thought to be his liver. It is smooth but tender. Not much loss of weight. No fever or jaundice. Temperature 38°, Pulse, 120, BP 130/95."

The exploratory laparotomy was carried out on January 26, 1925, by Dr. Adrian S. Taylor, Head of the Department of Surgery at PUMCH [4, 5]. It "revealed extensive involvement of the liver by carcinoma that had spread widely to the peritoneal surfaces of the abdominal viscera." As indicated in the autopsy report, during the remainder of his hospital stay he was "treated with radium," although no details were provided. However, as reported in *The New*

York Times [1], on February 18, 1925, "against the advice of hospital authorities, Dr. Sun was removed by friends and political associates to the headquarters of the Kuomintang, the former residence of Wellington Koo, previous Foreign Minister." Dr. Sun also acceded to the entreaties of those close to him and was treated by "old style Chinese doctors" [5], but his clinical condition continued to deteriorate. It was further noted in *The New York Times* article [1] that, "following his transfer from PUMCH he was growing weaker and weaker over the next few weeks, and shortly before his death he refused to accept food." Following his death on March 12, 1925, his body was placed in a wooden coffin, covered with a blanket [3], and transported from the Koo residence to PUMCH, where a limited autopsy was performed by Dr. Cash on March 13, 1925 "under the watchful gaze of his son, Sun Fo, and an entourage of military generals" [6]. Following this, "in the face of considerable opposition, the family had the courage to arrange for a Christian funeral service that was held in the beautiful auditorium of the PUMCH" [5].

Pathologic examination

According to a brief description of the autopsy itself [7], only a small section of tissue was taken for microscopic examination since the family had stipulated that no organs were to be removed from the body [6]. Subsequently, as described by Choa [8], during the Japanese occupation of Beijing, the military authorities announced that the internal organs, of which in reality there were none since they had never been removed from the body, and the microscopic section of the tumor, which had been kept in the Department of Pathology at PUMCH, would be reunited with Dr. Sun's body in the mausoleum in Nanjing, which had been completed in May 1929. According to Bowers and Choa [7, 8], this single microscope slide was sent to Nanjing in an enormous chest, and presumably it was placed in Dr. Sun's sarcophagus. The Japanese hoped that by this gesture they could boast that they had righted the wrong done to the Chinese national hero by foreigners, i.e., the Americans [7]. Consequently, we cannot show any photomicrographs of his tumor, but we have selected representative photomicrographs of an adenocarcinoma of the gallbladder (Fig. 4a) and a hepatocellular carcinoma (Fig. 4b) to illustrate the histopathologic differences between the two malignant tumors (Figs. 1 and 2). As indicated in the autopsy report (Fig. 2), the adenocarcinoma had infiltrated the liver and metastasized very widely both in the peritoneal cavity and to the thoracic cavity involving the lungs.

This pattern of metastasis was entirely consistent with a diagnosis of adenocarcinoma of the gallbladder [9, 10]. In contrast, "liver" cancer, and to be more specific, hepatocellular carcinoma, has a completely different pattern

CEN SEUNG SHAN (SUN YAT SEN), male 60 years. Autopsy - 294 Chinese.

Occupation: Died: March 12, 1925.

Service: Surgical Autopsy: March 13, 1925.

Autopsy by Dr. Cash. Hospital No. 9954.

ANATOMICAL DIAGNOSIS

Adeno carcinoma of the gall-bladder with obstruction of cystic duct; direct extension to liver and diaphragm; widespread metastasis to lungs, peritoneum, wall of ileum and colon; multiple constrictions of colon by carcinoma; healed cholecystitis; cholelithiasis; moderate generalized arteriosclerosis; slight diffuse scarring of the kidneys; cyst of left kidney; healed calcified tuberculosis of lungs; slight atrophy of heart; emphysema of lungs; ascites; pulmonary oedema; ascariasis.

CLINICAL HISTORY

ADMISSION:- January 26, 1925

FAMILY HISTORY:- Unimportant

PAST HISTORY:- Digestive disturbances for past ten years. No vomiting, pain or dysentery.

PRESENT ILLNESS:- Several months ago mass noticed in right upper abdomen. Recently noticed to be larger. Much discomfort and weakness. No fever or jaundice.

PHYSICAL EXAMINATION:- Large mass in right upper quadrant which is felt to be liver. It is smooth but tender. Not much loss of weight. No fever nor jaundice. temperature 38, Pulse, 120. B.P. 130/95. Exploratory laparotomy revealed extensive involvement of liver by carcinoma which had spread widely to the peritoneal surfaces of the abdominal viscera. During the remainder of the patient's stay in the hospital he was treated with radium.

MEDICAL EXAMINATION:- Urine; S.C. 1024, no sugar, albumin, casts, or blood. Blood: W.B.C. 17,600. R.B.C. 8,600,000.

I CERTIFY THAT THIS IS A TRUE COPY OF THE ORIGINAL

Ray J. Barth, M.D.



ROBERT J. HARRIS
Notary Public, State of Ohio
My Commission Expires 07-15-17

[Signature] 8/1/14

Fig. 2 A clearly legible retyped, notarized copy of the original Autopsy Report on Dr. Sun

of metastasis [11], which most frequently begins with invasion of the portal vein and from there to the lymph nodes (stage III disease), and then more distant anatomic sites including the lungs (stage IVb). As summarized by

Lazcano-Ponce et al. [10], over 90% of gallbladder carcinomas are adenocarcinomas. Gallstones and evidence of chronic cystitis are found in almost all cases, as was the case with Dr. Sun, and most of these are well to

DR. SUN YAT-SEN DIES IN PEKING

Chinese Leader Had Failed
Steadily Since an Operation
on Jan. 26 for Cancer.

HELPED TO OUST MANCHUS

Headed the New Government for a
Time—Latterly He Had Directed
the Southern Republic.

PEKING, Thursday, March 12 (Associated Press).—Dr. Sun Yat-sen, the South China leader, died this morning. Dr. Sun for some time had been suffering from cancer of the liver. Surgeons who operated on Dr. Sun at the Rockefeller Hospital here on Jan. 26 declared his case was hopeless and gave him only ten days to live. The Chinese leader clung to life, however, the ten days passing, leaving him weaker but still alive.

Fig. 3 Excerpt from Dr. Sun Yat-sen's obituary from *The New York Times* dated March 12, 1925 Copyright © *The New York Times*

moderately differentiated adenocarcinomas, although in the absence of the histologic sections of Dr. Sun's tumor, we cannot make any definitive statement regarding this. However, based on its aggressive pattern of growth, it could have been a poorly differentiated adenocarcinoma. Sadly, even today, patients with stage IVb gallbladder cancer have a very poor prognosis with a 5-year survival rate of only 2% [12].

Conclusions

In summary, what is remarkable to us is that it has taken 91 years after Dr. Sun's death to correct the historical record in the English language literature and

only recently in a non-medical Chinese online source [13] regarding the cause of his death. Purely by chance, it was an American pathologist visiting the Sun Yat-sen Memorial in Guangzhou in early May 2016 who noticed a barely legible, one-page document and examined it closely enough to see that it was a copy of the autopsy report of Dr. Sun, and it indicated that he had succumbed to an adenocarcinoma of the gallbladder and *not* liver cancer. Why then was it reported on March 12, 1925 in *The New York Times* [1], *TIME* magazine [2], and a Chinese newspaper [3] that Dr. Sun had died of liver cancer? Most probably, it was based on the observations of Dr. Taylor, who had performed the exploratory laparotomy and found that Dr. Sun's liver had been massively infiltrated with a malignant tumor. It was very reasonable, therefore, for him to conclude that Dr. Sun had liver cancer. However, following the autopsy on Dr. Sun, it was definitively established by Dr. Cash's histopathologic examination that the correct diagnosis was adenocarcinoma of the gallbladder, which grossly had been noted to be stone hard [3]. The incidence of liver cancer in present day China is 7.6 times greater than that of gallbladder cancer [14]. Since cancer statistics for China in 1925 were not available, we can only speculate on what the difference in incidences would have been at that time, but most certainly liver cancer was more common than gallbladder cancer, and hence Dr. Taylor's conclusion. If the information in Dr. Cash's autopsy report had been transmitted to the press back in March 1925, there would have been no need to correct the historical record. However, to the best of our knowledge, it was not. The final take-home message is that, even today, in the age of molecular medicine with a variety of sophisticated diagnostic techniques, a carefully performed autopsy still can provide answers to important questions that otherwise would remain unanswered.

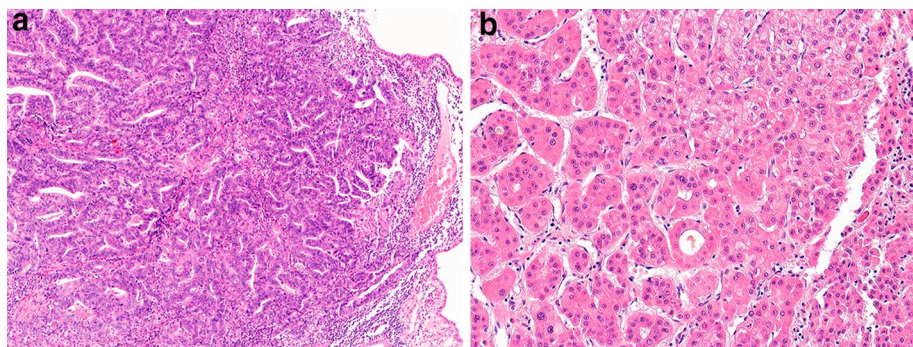


Fig. 4 Representative photomicrographs of **a** an adenocarcinoma of the gallbladder and **b** a hepatocellular carcinoma (magnification $\times 100$). The fact that Dr. Sun's tumor was highly invasive of the liver and had metastasized to a number of different organs suggests that it could have been a poorly differentiated adenocarcinoma [9]

Abbreviation

PUMCH: Peking Union Medical College Hospital.

Authors' contributions

RFB wrote the entire manuscript. JC searched the Department of Pathology files of Peking Union Medical College Hospital for additional materials relating to the autopsy on Sun Yat-sen, retrieved Chinese articles relating to his death, and provided photomicrographs. Unfortunately, the original Autopsy Report and the clinical records could not be found at the time of the writing of this report. Both authors read and approved the final manuscript.

Author details

¹ Department of Pathology, The Ohio State University, Columbus, OH 43210, USA. ² Department of Pathology, Peking Union Medical College Hospital, Beijing 100730, P.R. China.

Acknowledgements

We thank Mr. Tong Liu, General Manager, Beijing Capture Tech Co. Ltd. for taking RFB to visit the Sun Yat-sen Memorial Hall in Guangzhou, and Xiaohui Li for translating from Chinese into English an article from a March 15, 1925 Chinese newspaper relating to the death of Dr. Sun and retrieving articles from "people.cn" relating to Dr. Sun's death. We also thank Mr. Tom Rosenbaum, Archivist, Rockefeller Foundation Archives, Sleepy Hollow, New York, USA for searching the archives for information relating to Dr. Sun's illness, death, and autopsy. Finally, we thank Ms. Loretta Bahn for secretarial assistance in the preparation of this Letter.

Competing interests

We have no financial competing interests to declare. In relation to the manuscript, we do not have political, personal, religious, ideological, academic, intellectual, commercial competing interests to declare. The authors declare that they have no competing interests.

Received: 28 June 2016 Accepted: 25 July 2016

Published online: 02 September 2016

References

1. Dr. Sun Yat-sen dies in Peking. The New York Times. Released on March 12, 1925. <http://query.nytimes.com/gst/abstract.html?res=9F07EED8123FE733A25751C1A9659C946495D6CF&legacy=true>. Accessed 10 June 2016.
2. Foreign news: lost leader. Time. Released on March 23, 1925. <http://content.time.com/time/magazine/article/0,9171,881448,00.html>. Accessed 10 June 2016.
3. Important news. Qun Qiang Bao. Released on March 15, 1925.
4. Seventeenth annual report of the medical superintendent of the Peking Union Medical College Hospital for the year ending June 30. Bureau of engraving and printing. China: Peking; 1925.
5. Sharman L. Sun Yat-sen, his life and its meaning: a critical biography (re-issued 1968). California: Stanford University Press; 1934. p. 305–6.
6. Bullock MB. The oil prince's legacy: rockefeller philanthropy in China. Washington DC: Stanford University Press; 2011. p. 81.
7. Bowers JZ. Western medicine in a Chinese palace. New York: Josiah Macy Jr. Foundation; 1972. p. 113–4.
8. Choa GH. "Heal the sick" was their motto: The protestant medical missionaries in China. Hong Kong: The Chinese University Press; 1990. p. 152.
9. Brandt-Rauf PW, Pincus M, Adelson S. Cancer of the gallbladder: a review of forty-three cases. Hum Pathol. 1982;13(1):48–53.
10. Lazcano-Ponce EC, Miquel JF, Muñoz N, Herrero R, Ferrecio C, Wistuba II, et al. Epidemiology and molecular pathology of gallbladder cancer. CA Cancer J Clin. 2001;51:349–64.
11. Lee UT, Geer DA. Primary liver cancer: pattern of metastasis. J Surg Oncol. 1987;36(1):26–31.
12. American cancer society. Survival statistics for gallbladder cancer by stage. <http://www.cancer.org/cancer/gallbladdercancer/detailedguide/gallbladder-survival-rates>. Accessed 17 Jun 2016.
13. Clinical record copies from the Peking Union Medical College Hospital decrypt the real cause of death of Sun Yat-sen. Nanfang Daily. Released on Nov 11, 2013. http://epaper.southcn.com/nfdaily/html/2013-11/11/content_7243697.htm. [in Chinese].
14. Wang YC, Wei LJ, Liu JT, Li SX, Wang QS. Comparison of cancer incidence between China and the USA. Cancer Biol Med. 2012;9:128–32.

Submit your next manuscript to BioMed Central and we will help you at every step:

- We accept pre-submission inquiries
- Our selector tool helps you to find the most relevant journal
- We provide round the clock customer support
- Convenient online submission
- Thorough peer review
- Inclusion in PubMed and all major indexing services
- Maximum visibility for your research

Submit your manuscript at
www.biomedcentral.com/submit

